

The Use of Radiosurgery in Plastic Surgery and Dermatology

AYMAR E. SPERLI, M.D.

CHIEF OF SERVICE OF PLASTIC SURGERY

ASSISTANT PROFESSOR

DEPARTMENT OF PLASTIC SURGERY, MEDICAL SCHOOL SANTA CASA DE SÃO PAULO

SÃO PAULO, BRAZIL

For the last 13 years we have been using the CO₂ laser ray in plastic surgery, indicating it strictly in cases of restorative surgery of cavernous hemangiomas and eventually in benign dermatologic lesions. With the advent of new laser technologies, its indication extended to the resurfacing field, where results depend on patient selectivity. In our experience, we noticed that the CO₂ laser rays had poor results in attempts to remove tattooing and in incisions of skin and mucosa. Four years ago, we experimented with the radiofrequency equipment, whose mechanism of action in the tissues is very similar to that of the CO₂ laser rays (cellular volatilization). Following experimental studies in rats and human skin, we began to employ radiosurgery in daily clinical practice.

TECHNICAL COMMENTS

Radiosurgery is the cutting and/or coagulating of tissues, using a high frequency alternate current. The high frequency surgery and its results must not be confused with diathermy, electric cauterization, or spark producers. It is a method of simultaneous cutting and coagulating of the tissues. The effect of cutting, known as high frequency section, is executed without pressuring or crushing the tissue cells. This is the result of heat produced by the tissue resistance to the passage of a high frequency wave. The heat makes the intracellular water boil, increasing the cell inner pressure to the point of breaking it from inside to outside (explosion). This phenomenon is called cellular volatilization.

Electrosurgical generators are sometimes called by other terms. In Europe, electrosurgery is often called "surgical diathermy." In the United States, electrosurgical generators are also known as Bovie generators or electrocauterization machines. Because the waves used for

radiosurgeries are the mean frequency used in the FM radio, they are often called radiofrequency waves. One use of electrosurgery, as a method of cutting and coagulating tissues, was launched by physicists at the end of the last century. In the United States, electrosurgery became popular after Harvey Cushing and W. T. Bovie demonstrated its utility when performing neurosurgical operations with relatively no blood in the 1920s. Bovie developed two separate electrosurgical generators that were designed to produce cutting effects in tissues, similar to those obtained with a scalpel, or a coagulation effect on the tissue, which produced an excellent hemostasis.

Bovie's basic electrosurgical equipment, with separated currents for cutting and coagulating, was largely used in the United States between 1930 and 1960, only with slight modifications. Greater progress in electrosurgery occurred in the 1970s, when modern electrosurgical generators were developed. These circuits allowed the electrosurgical apparatus to produce complex wave forms and

to incorporate safety features. Modern radiosurgical equipment (Wavetronic 5000, Loktal Medical Electronics, Brazil, Sao Paulo, S. P.) allows the surgeon to perform more delicate surgeries with a larger margin of safety for the patient.

Our previous experience with CO₂ laser in plastic surgery provided a base for further clinical research on high frequency cellular volatilization.

For 4 years we have been working with this type of equipment with satisfactory results. We have routinely used this apparatus to perform small, medium, and large surgeries, including reduction mastoplasties, dermolipectomies, rhytidoplasties, dermatologic lesions, vicious scars, etc. The results, which have been largely presented in Congresses and publications in the medical community, derived from extensive experimental research and clinical application, leading us to extend the indication to peelings. However, basic knowledge of the physical phenomena that occurs in the use of such equipment is extremely important.

Basic Concepts in Radiosurgery and Principles of Electromagnetic Waves

The radiosurgical techniques are divided into two classes: monopolar techniques and bipolar techniques. In monopolar procedures, the electromagnetic waves of the active electrode passes through the patient body to the return electrode. In bipolar procedures, the electromagnetic wave flows from an active electrode to another active electrode through a limited amount of tissue between the two electrodes.

Modern radiosurgical equipment produces an electromagnetic wave of a very high frequency that reaches between 350,000 cps (cycles/second or 350 kilohertz) and 4,000,000 cps (4 Mhz - megahertz).

In addition to the relatively pure waves for cutting and coagulating, present equipment for radiosurgery also produce blended waves that combine the beneficial effects of radiosurgical cutting and the moderate degree of coagulation effects. It should be explained that, with almost all of the electrosurgical equipment, the quantity of hemostasis attained during cutting is not affected by the potency adjustment of the cutting module.

Effects of the High Frequency Waves on the Biological Tissues

Common electronic equipment may be compared to a table radio transmitting radio waves of low voltage. The high frequency active radiosurgical equipment may be compared to a transmitter through which RF waves of 4 Mhz at 140 watts flow. The earth plate is similar to an aerial antenna that picks up the waves and connects them to the earth.

With the radiosurgical equipment, five types of currents are obtained:

Type I current, fully rectified and filtered (90% cutting and 10% coagulation):

This current is indicated for pure cutting, produces a minimum of lateral heat (0 to 15 micras). It is used for very gentle and delicate cutting, avoiding carbonization and cellular destruction due to the minimum loss of lateral heat. This type of current is ideal when performing cuts near the bone, and is very useful for obtaining material for biopsy, grafts, and flaps; incisions for draining; and surgeries in mucosas.

Type II current: fully rectified (50% cutting and 50% coagulation):

This current is fully rectified for cutting and coagulating, producing more collateral heat (200 to 380 micras). It is the most used current due to its many applications in: cutting and coagulating, skin incision in aesthetic and restorative plastic surgery, diverse peelings, extirpation of skin and mucosa tumors. The effect of incision and coagulation act simultaneously at the electrode point. This type of

current must avoid bone. It is an excellent indication for nerve extirpation, resection of actinic and seborrhoeic keratosis, keloid resection, and other indications.

Type III current, partially rectified (90% coagulation and 10% cutting):

This current is indicated for hemostasis and coagulation with more lateral heat (about 500 to 700 micras). It is used in dermatologic procedures, such as the

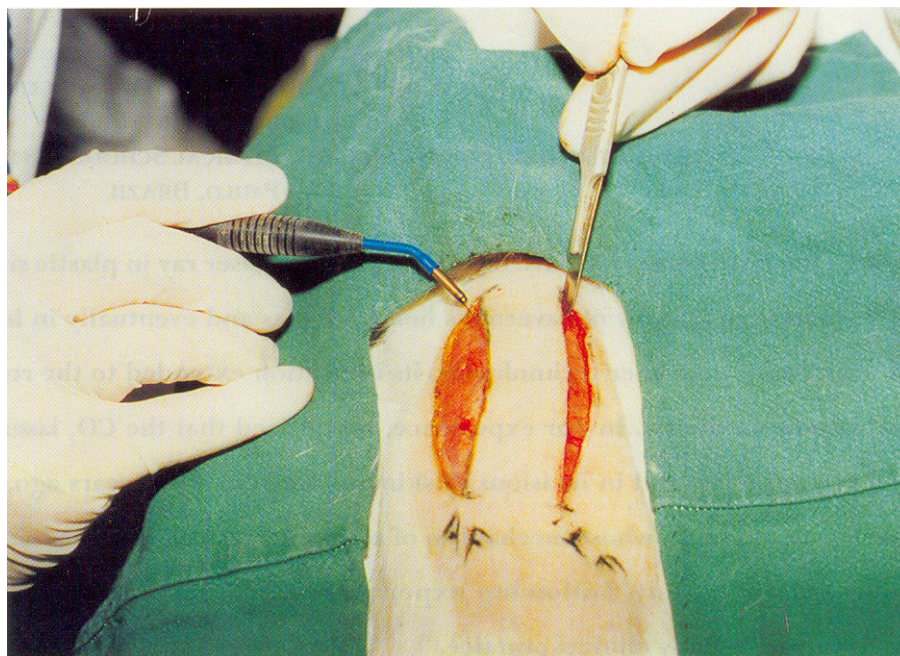


Figure 1. White Wistar rat of the research group. Left incision: high frequency scalpel. Right incision: cold blade scalpel.

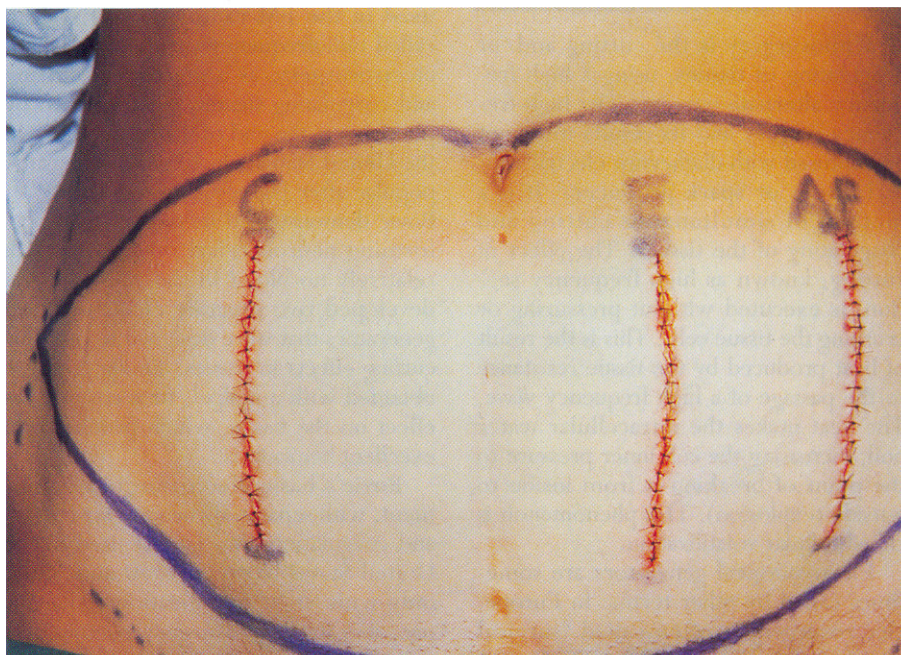


Figure 2. Hypogastric region of patient to be subjected to abdominal dermolipectomy within 2 months. Performed longitudinal incisions with three types of scalpel: scalpel C: cold blade; scalpel E: low frequency; scalpel RF: high frequency. From these regions, fragments were removed for histological examination on days 8, 30, and 60.

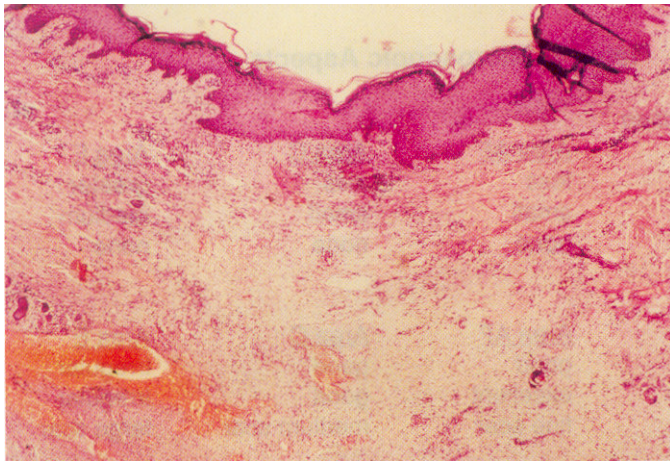


Figure 3. Histological aspect on the 8th day: AF area (incision with high frequency scalpel): central dermis with cicatricial proliferation, with predominance of capillary vessels over the collagen. The reaction inflammatory is low in the periphery and absent in the central area.

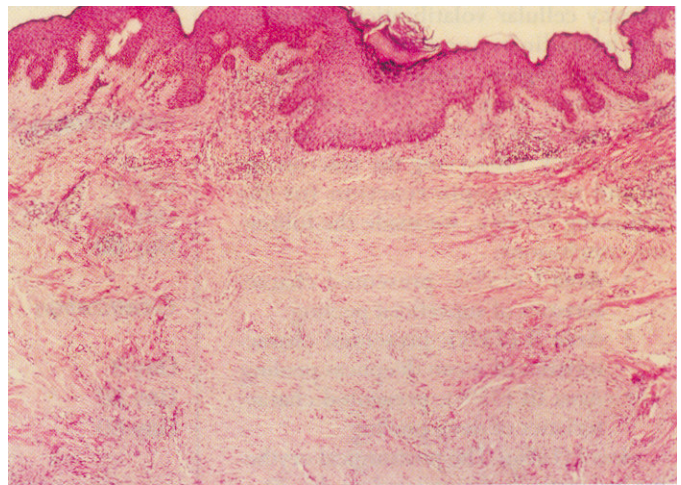


Figure 4. Histological aspect on the 8th day: C area (incision with cold blade scalpel): the dermis show central fibrosis in all thickness. In the periphery low reaction inflammatory is observed.

treatment of telangiectasis, depilation, epistaxis, etc.

Type IV current of fulguration:

This current is indicated to destroy tissues by dehydration and is employed in the odontologic field.

Type V current, bipolar:

This current is used in microsurgery and also as hemostatic current of high precision in wet or dry areas, using a pair of tweezers as electrodes.

MATERIAL AND METHODS OF RESEARCH

First Study

We selected 30 white Wistar rats, weighing 250 g of the same origin and age. After depilating the back of each

animal, we made longitudinal incisions, varying the type of scalpel. (Fig. 1):

Left side = cutting with high frequency scalpel

Right side = cutting with cold blade scalpel

After the incisions were sutured, histologic cuts were performed on postoperative days 8, 15, 30, and 60. The results were reviewed under the "double blind" evaluation process, and we drew conclusions under the macroscopic and microscopic points of view.

The macroscopic result showed more inflammatory reaction in the right side (incision with cold blade scalpel) on the eighth day, tending to become equal on the sixtieth day.

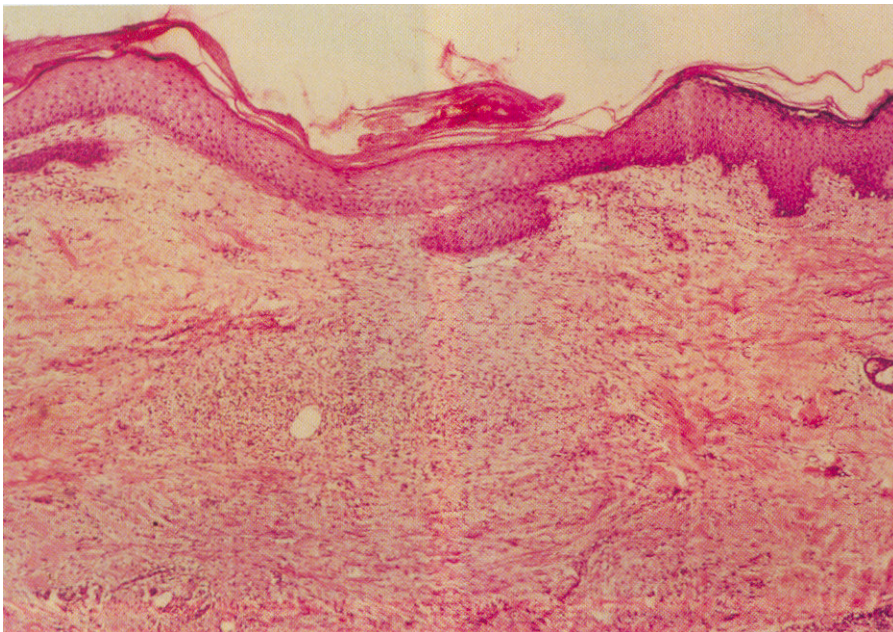


Figure 5. Histological aspect on the 8th day: E area (incision with low frequency scalpel): central dermis with fibro-capilar proliferation. The reaction inflammatory is moderate, as in the cicatricial zone as in the peripheral dermis.

Left side (incision with radiofrequency scalpel) showed a delay in the fibrogenesis and increase of neovascularization on the thirtieth day, which led us to predict a better future cicatrization.

Second Study

Five Caucasian female patients between 25 and 50 years of age, presenting with abdominal lipomatosis, primiparous, and no striae in the abdomen. Each patient was subjected to abdominal dermolipectomy within a 2-month period.

Three cutaneous incisions of 8 cm in length, located in the hypogastrium (area to be excised in the abdominal dermolipectomy act) were performed in these patients (Fig. 2), according to the following criterium:

Area AF: incision with high frequency scalpel

Area C: incision with cold blade scalpel

Area E: incision with common low frequency electric scalpel

Once the incisions were sutured, histologic cuts were performed on postoperative days 8, 30, and 60 (Figs. 3-5), comparing the macroscopic and microscopic aspects of the various incisions in the five patients (Tables 1,2).

Third Study

Three Caucasian female patients between 40 and 50 years of age, presenting with abdominal lipomatosis and as future candidates to abdominal dermolipectomy were selected.

In these patients, we performed peeling in a 16 cm² area with high fre-

quency cellular volatilization (resurfacing by radiofrequency) in the hypogastric region, using three different potencies: area I = 15%, area II = 25%, and area III = 35% of the apparatus potency. Observing the macroscopic and microscopic reaction for the following 30 days, we made the following conclusions:

- Area I (15%): presented characteristics of superficial peeling
- Area II (25%): presented characteristics of mean deepness peeling
- Area III (35%): presented characteristics of deep peeling

Area I (15%): The postsurgical erythema had virtually disappeared on day 30.

Area II (25%): Showed a still visible, but not very intense, erythema.

Area III (35%): The erythema was still quite visible.

Comparing the histological results of peeling with radiofrequency and peeling of CO₂, we found many similarities in the histological characteristics.

Fourth Study

Thirty Caucasian female patients between 23 and 40 years of age, presenting ptosis and/or bilateral mammary hypertrophy already in the clinical observation phase were selected. The high frequency scalpel was used to operate on the left breasts while the cold blade scalpel was used to operate on the right breasts.

Photographs were taken of each patient up to a postoperative period of 2 years, comparing the final result of the scars presented in the left and right breasts of each patient (Figs. 6,7). Our conclusions for this work were:

- 60% (21 patients) presented better scars in the left breast
- 36.5% (eight patients) presented similar scars in both breasts
- 3.3% (one patient) presented a better scar in the right breast

COMMENTS AND CONCLUSIONS

A reduction in resistance and a greater precision in the cut with the high frequency scalpel has led us to increase our use in this type of cutting in routine cases (great sized surgeries, such as mastoplasties and dermolipsectomies) as well as small surgeries (removal of naevus, skin tumors, vicious scars, etc.). The long-term clinical observation seems to indicate better cicatricial results.

Some topics raised by the anatomopathologist regarding the microscopic aspect lead us to conclude that:

Table 1. Microscopic Aspects

Inflammatory Reaction

	<u>Area AF</u>	<u>Area C</u>	<u>Area E</u>
Day 8	less	less	greater
Day 30	small	small	medium
Day 60	none	none	none

Cicatrization

	<u>Area AF</u>	<u>Area C</u>	<u>Area E</u>
Day 8	good	good	irregular
Day 30	excellent	good	irregular
Day 60	fine scar	medium scar	large scar

Table 2. Macroscopic Aspects

<i>Area AF</i>	Delay of the fibroblastic phase and presence of neovascularization, with increased vascularization as of the 30th day.
<i>Area C</i>	Acceleration of the fibroblastic phase and absence of neovascularization significant areas.
<i>Area E</i>	Presence of residual inflammatory reaction still on the 30th day, with a certain tissular disorganization in the "cicatrization cold zone." Absence of neovascularization.

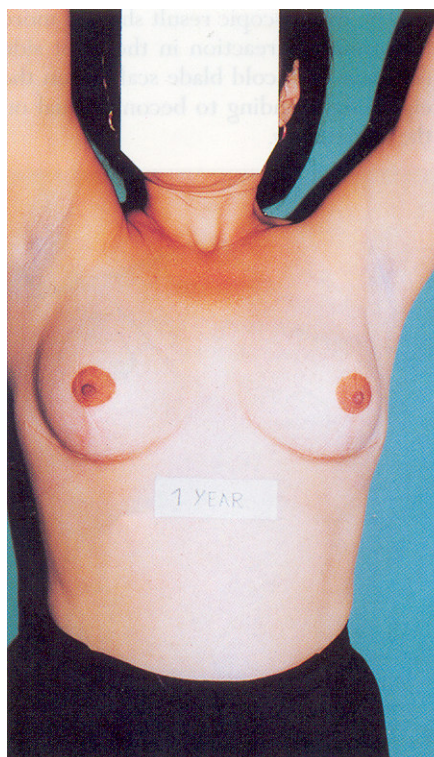

Figure 6. Patient #1: Postoperative of reducing mastopasty, made 1 year ago. Left breast, operated with high frequency scalpel. Right breast, operated with cold blade scalpel. A better cicatrization on the left side is observed.

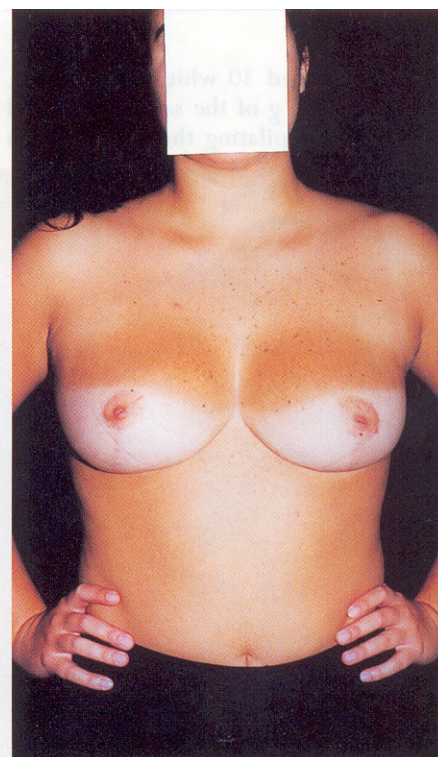

Figure 7. Patient #2: Postoperative of reducing mastopasty, made 2 years ago. Left breast, operated with high frequency scalpel. Right breast, with cold blade scalpel. In this case, both scars presented similar conditions.

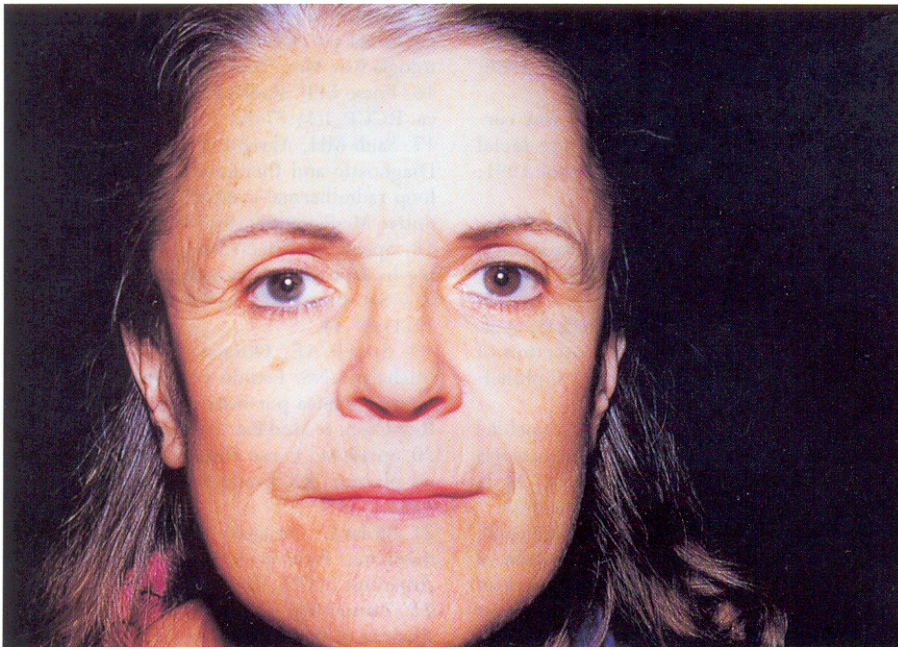


Figure 8. Patient #3: Preoperative of patient aged 53 years old, presenting cutaneous photoaging.

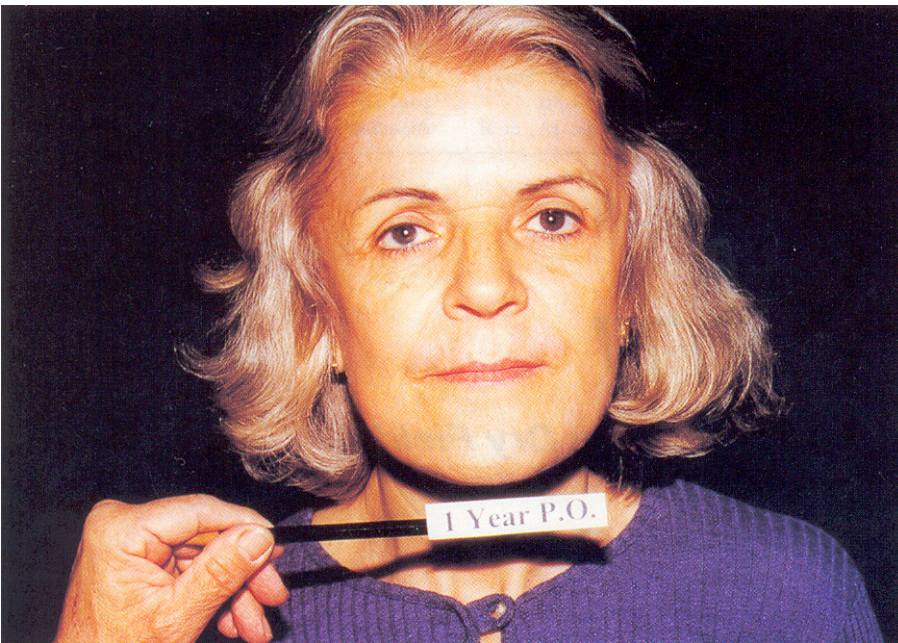

Figure 9. Patient #3: Postoperative, after 1 year of resurfacing (full face), performed with electrosurgery (35% of the equipment of radiofrequency potency). Deep peeling.

ty of 35% of the apparatus potency and with the current totally rectified and not filtered with proper electrode.

This procedure was used in patients treated in ambulatorial surgical centers, with sedation of 15 mg of Midazolam, administered 20 minutes before the surgical procedure. Wetting the skin with physiological solution and applying gentle pressure on the skin in quick brushing movements, we observed that the skin surface layer detached itself easily, showing a whitish and totally bloodless area that is continuously dried by the assistant with a dry gauze. The time spent for a total face peeling was approximately 60 minutes.

To complete the surgery, we anointed the patient face with a slight layer of solid vaseline. In a few cases the patients complained of burning after 3 hours, which was treated with the application of lidocain jelly (1 hour) and manutention with nutrient or hydrating cream.

In cases of full face peeling, we observed that the facial oedema after 24 hours persisted for 3 days and diminished progressively until the sixth day. The exposed face was maintained with hydrating creams with solar blocker. The characteristic crust of deep peelings appeared at the third day and little by little detached itself and was eliminated around the tenth postoperative day. In cases of deep peeling, the postpeeling erythema disappeared only through the fourth to the sixth months, as normally happens with the other deep peeling procedures. In cases of peribuccal and periorbicular areas, we used the middle deepness peeling, observing the disappearance of the erythema around the third month (middle deepness peeling).

During the time of persistence of the postsurgical erythema, the patient's skin was treated with creams based in hydratants, solar photoprotector, and alpha-hydroxi-acids. We did not obtain any satisfactory results in the cases of tattoo removal, although our selection included dark pigments, superficially placed with very mild pigmentation density. We believe that in these cases, Rubilaser is the best treatment to explode the pigment without injuring the skin. The patients subjected to regional resurfacing and full-face were followed up during a 12-month post-treatment period (Figs. 8,9).

The frequent search for methods that enhance scar quality and the facility of the

1. The presence of greater neovascularization and the delay of the fibroblastic phase with the use of high frequency scalpel made a better prognosis possible for normal scars, and created more favorable conditions for cases of pathologic scar corrections (hypertrophies, keloids) for the postoperative use of complementary resources, such as corticotherapy, betatherapy, or compression (Figs. 3-5). These results warrant further studies.

2. A more regular cut, performed with the current fully rectified and not

filtered (perpendicular to the cutaneous surface), allows a better (afrentamento) margin during the skin suture, which would permit a better cicatricial prognostic.

We could easily perform deep peeling in the programmed regions, provided that these are anesthetized with Lidocain solution at 0.2% with adrenalin at 1/200,000 (total volume for a complete face = 100 cm³), by using the radiosurgical apparatus for high frequency cellular volatilization with an intensi-

technical performance, led us to regularly use RF equipment in the section of skin and mucosa, as well as the extirpation of benign lesions. We have been routinely using the regional resurfacing (peribuccal and periorbicular areas) complement in cases of rhytidoplasty. **STI**

REFERENCES

1. Amorocho NH, Guardiola ME. Cono cervical con radiocirugía: alternativa en diagnóstico y tratamiento de neoplasia intraepitelial del cervix. *Revista Colombiana de Obstetricia y Ginecología* 1993;44(4):297-300.
2. Bisaccia E. Blepharoplasty with radiosurgical instrumentation. *Cosmetic Dermatology* 1995; 8 (2).
3. Bosniak S, Zilkha F, Zilkha MC. Cosmetic radio-blepharoplasty. *International Journal of Aesthetic and Restorative Surgery* 1995; 3(1): 53-56.
4. Brown JS. Radio-surgery. Minor surgery - a text and atlas. Chapman & Hall Medical, third edition, 1997; Chapter 42, 300-26.
5. Candiani JO, Gutiérrez LMF, Rodríguez JAC. Rinofima; tratamiento con radiocirugía. Reporte de un caso. *Dermatología Rev Mex* 1996; 40 (1) : 46-49.
6. Fitzpatrick RE. Renovação da pele com laser CO2 ultrapulse. *Revista de Cosmiatria & Medicina Estética* 1995; 4(2): 16-30.
7. Garden JM, O'Banion MK, Shelnitz LS, et al. Papillomavirus in the vapor of carbon dioxide laser - treated verrucae. *JAMA* 1988; 259(8) : 1199-1202.
8. Harris D, Noodleman R. Using a low current radiosurgical unit to obliterate facial telangectasias. *J Dermatol Surg Oncol* 1991; 17: 382-84.
9. Hofmann A, Wustner M, Ciric B. Radio-wave surgery case report. *International Journal of Aesthetic and Restorative Surgery* 1996; 4(2): 131-33.
10. Hurwitz JJ, Johnson D, Howarth D, et al. High-frequency radio wave electrosection of full-thickness eyelid tissues. *Can J Ophthalmol* 1992; 28 (1):28-31.
11. Jou DP, Tintore LMP, Iglesias X. Papel del asa diatérmica en el diagnóstico de la patología cervical. Resultados en el tratamiento de la CIN. *Acta Ginecológica* 1993; L (8) : 320-23.
12. Kadri MKM, Eshak EA, Zaki MS, et al. Clinical and histopathological evaluation of radiofrequency in the surgical management of malignant skin lesions. *Egypt J Plast Reconst Surg* 1995;19(2):93-98.
13. Kainz C, Tempfer C, Sliutz G, et al. Radiosurgery in the management of cervical intraepithelial neoplasia. *Journal of Reproductive Medicine* 1996;41(6):409-14.
14. Murute J, Murute E. Treatment of dry eye by blocking the lacrimal canaliculi. *Survey of Ophthalmology* 1996;40 (6):463-80.
15. Piñeyro U, Elizondo A, Cueva JA, et al. Tratamiento de la onicocriptosis. Matriectomía parcial con radiocirugía. *Dermatología Rev Mex* 1996;40(6):400-03.
16. Posse LFP. Radiocirugía en cirugía plástica. *RCCP*;3(1):17-22.
17. Saidi MH, Akright BD, Setzlee FD, et al. Diagnostic and therapeutic conization using loop radiothermal cautery. *Journal of Reproductive Medicine*;38(10):775-79.
18. Sperli AE. Electrosurgical peeling (peeling by high frequency cellular volatilization). *Rev Soc Bras Cir Plast Estet Reconstr* 1996; 11(1):21-34.
19. Sperli AE, Gonçalves de Freitas JO, Michalany NS. Estudo reacional orgânico da injúria cutânea por bisturi de alta frequência. *Rev Cosm & Med Est* 1995;3(2):40-45.
20. Sperli AE. O uso do laser de CO2 em cirurgia plástica. *XX Congr Bras Cir Plast Brasília* 1983.
21. Stolar E, Turjansky E. Radiofrecuencia en medicina. *Revista de la Asociación Médica Argentina DATE*;106(1):40-50.
22. Turner RJ, Cohen RA, Voet RL, et al. Analysis of tissue margins of cone biopsy specimens obtained with "cold knife," CO2 and Nd:YAG lasers and radiofrequency surgical unit. *Journal of Reproductive Medicine* 1996;37(7): 607-10.
23. Valinsky MS, Hettinger DF, Gennet PM. Treatment of verrucal via radiowave surgery. *Journal of the American Podiatric Medical Association* 1990;80(9):482-88.